

Severe acute renal failure after massive attack of Africanized bees

Sir,

Acute renal failure (ARF) is a rare complication of massive attack by Africanized bees and can be observed 48–72 h after the accident [1]. There are nearly 30 cases reported in the literature [2,3]. We report the case of a massive attack of Africanized bees and severe ARF with full recovery of the renal function.

Case. A 55-year-old man was victim to a massive attack by Africanized bees (>500 bee stings) in a rural area in São Paulo, Brazil. On admission to hospital, widespread erythematous and painful papules were found on his body. The patient was discharged from the hospital after oral medication. Six days following the accident the patient sought further emergency medical assistance, complaining of generalized oedema, urinary volume reduction, weakness, pallor and dyspnea. No laboratory evaluation was performed and he was discharged from hospital. Ten days after the accident, the patient returned, presenting with dyspnea, pallor, hypertension, tachycardia, oliguria and generalized oedema. Laboratory exams presented anaemia (haematocrit, 16%; haemoglobin, 5.9 g/dl) and renal function failure (serum creatinine, 27 mg/dl; blood urea nitrogen, 221 mg/dl; serum potassium, 7.8 mEq/l). He was transferred to the Intensive Care Unit (ICU) and endovenous hydration and transfusion of erythrocyte concentrate were initiated. Continuous peritoneal dialysis through Tenckhoff catheter was performed. Clinical improvement was observed on the second day of treatment, but diuresis recovery was recorded only 20 days after the accident. Peritoneal dialysis was interrupted at 23 days after the accident. Seventy-one days after the attack he had full recovery of renal function (Figure 5).

Comment. Africanized bee attack may result in a simple local inflammatory reaction to anaphylactic shock. The resulting intoxication provoked by the venom has been reported as hepatic, respiratory, renal and circulatory failures [2]. Isolated ARF is considered a rare complication and was established 48–72 h after the accident. It was due to a bee venom reaction with direct nephral toxic action and is able to induce haemolysis, rhabdomyolysis and renal ischaemia [3,4].

The patient in this case experienced ARF without other organ lesions. Surprisingly, preventive measures and diagnosis were not reported at the initial medical consult. Haemolysis and rhabdomyolysis could not be identified

through laboratory exams; however, the severe anaemia pointed to a haemolysis-associated picture.

In cases recently reported, ARF was diagnosed and dialysis was indicated up to 48 and 72 h after the accident. The latest ARF diagnosis was carried out 11 days after the accident with partial renal function recovery at 9 month follow-up [1]. Peritoneal dialysis associated with plasmapheresis or haemodialysis have been prescribed as dialytical methods [5]. In our work, the ARF diagnosis was made 10 days after the accident. This late diagnosis and extended dialytical treatment, however, did not prevent the entire recovery of renal function, which has not been described yet in the literature.

Department of Internal Medicina Daniela Ponce Gabriel
Hospital das Clínicas da Antonio Gonçalves Rodrigues Jr
Faculdade de Medicina de Botucatu
Universidade Estadual Paulista Renata Cristina Barsante
UNESP Vanessa dos Santos Silva
Rubião Júnior Jacqueline Teixeira Caramori
PO Box 584 Luís Cuadrado Martim
CEP 18618970 Pasqual Barretti
São Paulo André Luís Balbi
Brazil
Email: dponcegabriel@uol.com.br

1. Diaz-Sanches CL, Lifshitz-Guinberg A, Quinines-Galvan A. Survival after massive Africanized honeybee stings. *Arch Intern Med* 1998; 158: 925–927
2. Hommel D, Hulin A. Multiple African honeybee stings and acute renal failure. *Nephron* 1998; 78: 235–236
3. Munoz-Arizpe R, Velasques-Jones L, Valencia-Mayoral P. Africanized bee stings and pathogenesis of acute renal failure. *Nephron* 1992; 61: 478–484
4. Kim YO, Yoon SA, Kim KJ *et al.* Severe rhabdomyolysis and acute renal failure due to multiple wasp stings. *Nephrol Dial Transplant* 2003; 18: 1235
5. Beccari M. Dialysis or plasmapheresis for acute renal failure due to Africanized honeybee stings. *Arch Intern Med* 1999; 159: 1255–1256

doi:10.1093/ndt/gfh440

Hypocomplementaemic urticarial vasculitis syndrome and acute renal failure with cryoglobulin (–) hepatitis C infection

Sir,

Hypocomplementaemic urticarial vasculitis syndrome (HUVS) is a rarely observed disease. Diagnostic criteria are the presentation of chronic urticaria and hypocomplementaemia, with at least two of the following: vasculitis findings from dermal biopsies, arthralgia or arthritis, glomerulonephritis, uveitis or episcleritis, repeated abdominal pain and the presence of C1q precipitating factor in the plasma [1]. Infection with hepatitis C virus (HCV) has been associated with a variety of extrahepatic disorders, including renal disease and vasculitis [2]. The association of cryoglobulin (–) HCV infection and HUVS is rare. We present a patient with cryoglobulin (–) HCV infection and severe renal failure observed in HUVS which did not respond to classical treatment.

Creat (mg/dl)

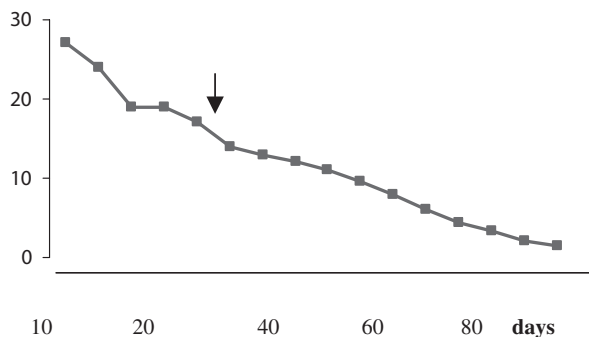


Fig. 1. Patient's renal function (serum creatinine, mg/dl) at nephrological follow-up. The sign shows the interruption of peritoneal dialysis.